

## Resting HyperQ: A Novel ECG Technology for Diagnosis and Monitoring of Patients with Acute Coronary Syndrome

### Introduction

BSP is developing a new line of products, based on HyperQ™ technology, for highly-accurate early detection and monitoring of acute myocardial ischemia. Relying upon sound scientific foundations as well as promising results of on-going clinical studies, it is anticipated that these products will provide valuable new tools for a variety of clinical applications, including resting ECG, bedside monitoring and home telehealth. This whitepaper describes the technology and the clinical data supporting its efficacy.

### The Clinical Need

Chest pain is a leading cause for emergency department (ED) visits, with 6 million annual such cases in the US alone [1]. Despite the wealth of knowledge available about acute coronary syndrome (ACS), this condition continues to be among the most difficult to diagnose or exclude. **Nearly half of patients hospitalized for unstable angina eventually receive a non-cardiac-related diagnosis [2]. Nonetheless, 2%-5% of patients with acute myocardial infarction (MI) are inappropriately discharged from the ED [2,3] and consequently have poorer prognosis [4].** Electrocardiography (ECG) remains the primary cornerstone in risk-stratification of patients with chest pain. However, the initial 12-lead resting ECG is limited by low sensitivity, especially in patients with non ST-elevation MI and unstable angina [5]. The initial ECG findings have been reported to be diagnostic of acute injury or ischemia in 40% to 65% of patients with acute MI [6]. The pattern of dynamic ST-segment changes (“intermittent reperfusion”) is common in the early hours of acute MI, further decreasing the diagnostic value of the initial resting ECG. Accurate early diagnosis or exclusion of acute myocardial ischemia is therefore important in order to improve the prognosis of actual ACS patients, while reducing the staggering healthcare costs of chest pain workup in patients without ACS.

### Scientific Foundations

Conventional analysis of ST segment deviations aims to detect repolarization abnormalities. However, myocardial ischemia also induces changes in the depolarization phase of the electrical cardiac cycle [7]. These depolarization changes can be detected and quantified using analysis of the high-frequency components of the QRS complex (HFQRS). HFQRS analysis, typically performed in the frequency range of 150Hz to 250Hz, quantifies the subtle changes in the propagation of the depolarization wavefront throughout the myocardium. Myocardial ischemia reduces the myocyte-to-myocyte conduction velocity, causing reduced intensity and altered morphology of the HFQRS components. It was observed that following coronary artery occlusion, HFQRS signals present distinct morphologic pattern, which was termed ‘reduced amplitude zone’ (RAZ, Figure 1). Studies in animal models, humans undergoing percutaneous coronary intervention, and exercise testing have consistently demonstrated that HFQRS analysis provides sensitive indication of myocardial ischemia with incremental diagnostic value over conventional ECG [8-19].

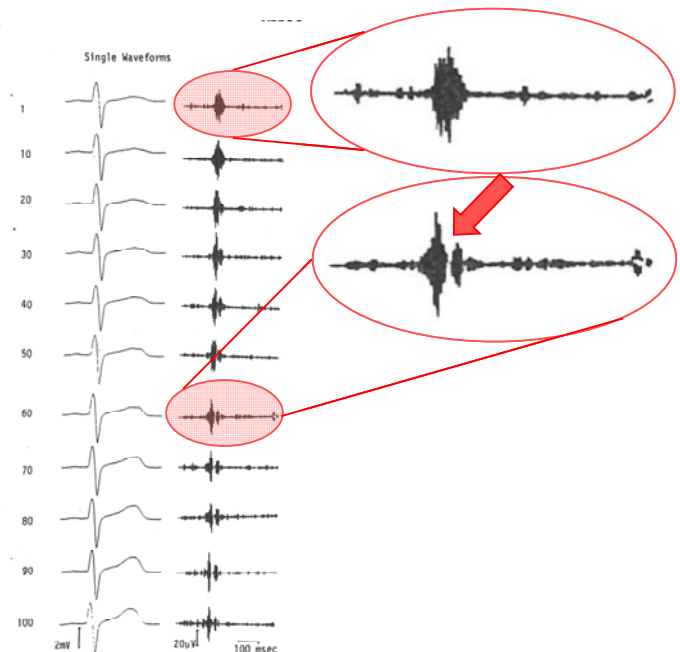


Figure 1: Traces of nonfiltered (left) and high-frequency (right) ECG following complete occlusion of LAD artery of an open chest dog. RAZ morphology is observed 40 waveforms (~20 seconds) after occlusion. No significant ST changes are present (data from [8]).

## Resting HyperQ Analysis

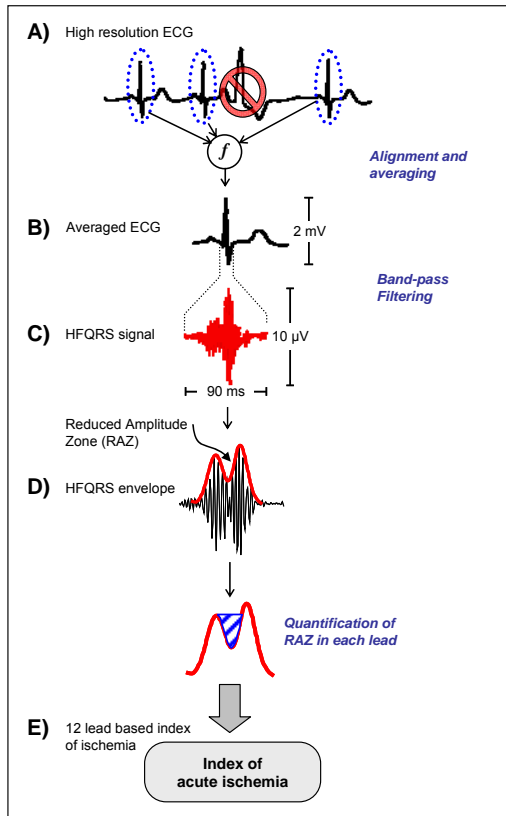


Figure 2: HyperQ Analysis (see text for details)

HyperQ analysis is performed using a proprietary algorithm developed by BSP (Figure 2). The analysis algorithm first uses template-based correlation to identify valid QRS complexes and exclude noisy or ectopic beats (A). Accurate sub-sample beat alignment, followed by beat averaging is then used to obtain high signal-to-noise ratio (B). Each valid average QRS complex is filtered by a band-pass digital filter in the high frequency band (typically, 150Hz to 250Hz) (C). The time-domain envelope of the HFQRS complex is then calculated using a Hilbert transform (D). Reduced area zones (RAZ) are detected and quantified using a novel index, named High Frequency Morphology Index (HFMI). HFMI values, measuring the relative area of the basins in the HFQRS signal envelope (in %) are calculated per lead and used as a diagnostic index of acute myocardial ischemia (E).

An example of applying this analysis to high-resolution ECG of a patient with ST-elevation myocardial infarction is given below (Figure 3, left). During the patient's admission to the intensive coronary care unit (ICCU), the average HFQRS shows significant RAZ morphology, with HFMI value of 15%. Following Percutaneous coronary intervention (PCI), HFQRS morphology gradually reverts to normal, and HFMI decreases to 0% 24 hours after the intervention. Comparing average HFMI values of 30 patients admitted to the ICCU (Figure 3, right) reveals a trend of decrease in HFMI in patients with either urgent or spontaneous reperfusion [15].

## Clinical Studies

Resting HyperQ technology has been developed and evaluated using carefully-designed clinical studies. The feasibility of the analysis and the characteristics of HFQRS signals during acute myocardial ischemia were first determined in patient undergoing intracoronary balloon occlusion [14] and patients admitted with acute myocardial infarction [15].

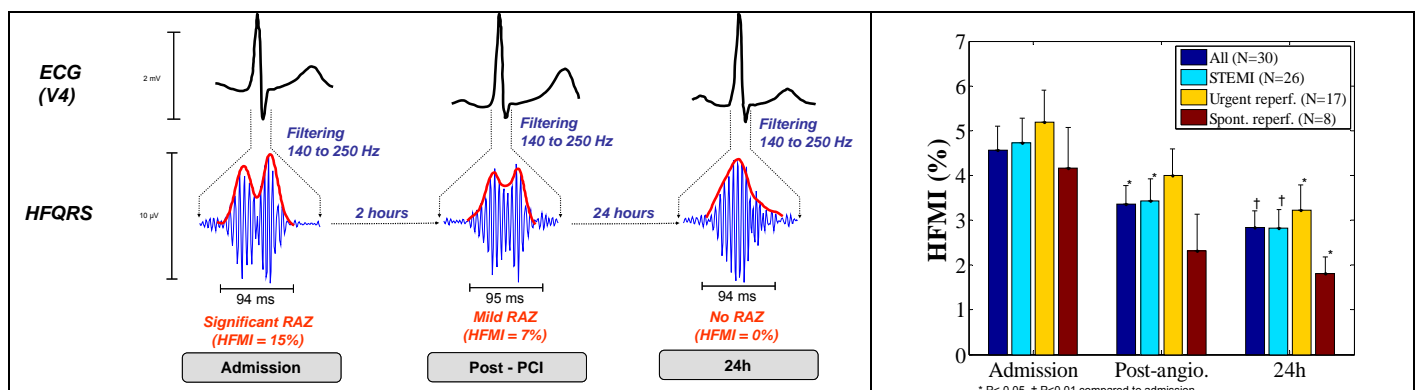


Figure 3: (Left) ECG and HFQRS signals acquired at admission, post-revascularization and after 24 hours from a 41 year-old male with ST-elevation MI. Note the profound change in the HFQRS signal morphology, showing a significant reduced amplitude zone (RAZ) during admission, which is resolved after 24 hours. Conventional ECG does not exhibit ischemic pattern at the time or recording. (Right) Comparison of average HFMI values at ICCU admission, post angiography and after 24 hours. Error bars represent standard error of the mean (data from [15]).

The application of the technology for detection of acute ischemia in patients presenting to the emergency department with chest pain is being evaluated in two on-going studies, with promising interim results [16,17]. The application of the technology for continuous patient monitoring was assessed as well [18,19]. The following table summarizes the published results and on-going clinical studies using HyperQ technology:

	Study	Population	Aim	Main Results
Feasibility	STAFF-III (US)	64 pts undergoing intracoronary balloon occlusion (PTCA)	Feasibility of detecting acute ischemia caused by intra-coronary balloon occlusion	HFQRS morphology changes were a sensitive (84%) and specific (80%) index of acute myocardial ischemia [14]
	Soroka-CCU (Israel)	30 pts with acute MI, before and after revascularization	Characterization and trend of HFQRS morphology changes in pts with acute myocardial infarction	HFQRS morphology index decreased from admission to discharge (4.6±2.9 % vs. 2.8±2.1 %, P<0.01) [15]
ACS Diagnosis	Soroka-ED (Israel) <i>In-progress</i>	300 pts presenting to the emergency department with chest pain (interim analysis: 187 pts)	The usefulness of HFQRS analysis in triaging patients with chest pain in the ED	HFQRS morphology index was higher in patients with ACS, compared to non-ischemic. HFQRS analysis was more sensitive than ECG in detecting non T-elevation ACS (62% vs. 30%, P<0.001) [16,17]
	Basel-ED (Switzerland) <i>In-progress</i>	485 pts presenting to the ED with chest pain	Early detection and monitoring of myocardial ischemia using HFQRS analysis	Preliminary results support the findings of the former study (Soroka-ED)
ACS Monitoring	Sheba-CPU (Israel)	43 pts monitored at the chest-pain unit	Feasibility of detecting ischemic events by continuous HFQRS monitoring	The number of leads with high HFMI values was larger in patients with high likelihood of ischemic events (2.6±1.3 vs. 1.6±1.1 P<0.02) [18]
	IMMEDIATE-AIM (US)	171 pts with suspected ACS, monitored by Holter	Retrospective analysis of the usefulness of HFQRS monitoring in triage of pts with chest pain	The number of leads with high HFMI values was larger in patients with MI or unstable angina, compared to non-ischemic (2.8±1.0 and 2.5±1.2 vs. 1.2±0.7, P<0.005) [19]

## Conclusions

Resting HyperQ is a novel technology for detection and monitoring of acute myocardial ischemia. Based on solid scientific foundations, and validated in published and on-going clinical studies, HyperQ is a promising new tool for risk stratification of patients with suspected myocardial ischemia. Incorporating HyperQ in the routing workup of patients with chest pain can potentially improve quality of care while reducing medical costs.

## References

1. Niska R, Bhuiya F, Xu J. National Hospital Ambulatory Medical Care Survey: 2007 emergency department summary. Natl Health Stat Report 2010;1-31.
2. Farkouh ME, Smars PA, Reeder GS, et al. A clinical trial of a chest-pain observation unit for patients with unstable angina. Chest Pain Evaluation in the Emergency Room (CHEER) Investigators. N Engl J Med 1998; 339:1882-8.
3. Pope JH, Aufderheide TP, Ruthazer R, et al. Missed diagnoses of acute cardiac ischemia in the emergency department. N Engl J Med 2000; 342:1163-70.
4. Lee TH, Goldman L. Evaluation of the patient with acute chest pain. N Engl J Med 2000; 342:1187-95.
5. Decker WW, Prina LD, Smars PA, Boggust AJ, Zinsmeister AR, Kopecky SL. Continuous 12-lead electrocardiographic monitoring in an emergency department chest pain unit: an assessment of potential clinical effect. Ann Emerg Med 2003; 41:342-51.
6. Fesmire FM, Percy RF, Bardoner JB, Wharton DR, Calhoun FB. Usefulness of automated serial 12-lead ECG monitoring during the initial emergency department evaluation of patients with chest pain. Ann Emerg Med 1998; 31:3-11.

7. Downar E, Janse MJ, Durrer D. The effect of acute coronary artery occlusion on subepicardial transmembrane potentials in the intact porcine heart. *Circulation* 1977; 56:217-24.
8. Abboud S, Smith JM, Cohen RJ. Et al. High frequency electrocardiography of three orthogonal leads in dogs during a coronary artery occlusion. *PACE* 1989;12:574-581.
9. Abboud S et al. Detection of transient myocardial ischemia by computer analysis of standard and signal averaged high frequency ECG in patients undergoing percutaneous transluminal coronary angioplasty. *Circulation* 1987;76:585-96.
10. Pettersson J et al. Changes in high-frequency QRS components are more sensitive than ST-segment deviation for detecting acute coronary artery occlusion. *J Am Coll Cardiol* 2000;36:1827-34
11. Toledo E, Lipton JA, Warren SG, et al. Detection of Stress-Induced Myocardial Ischemia from the Depolarization Phase of the Cardiac Cycle - A Preliminary Study. *J Electrocardiol* 2009; 42:240-9
12. Sharir T et al. The Use of ECG Depolarization Abnormalities for Detection of Stress-Induced Ischemia as defined by Myocardial Perfusion Imaging. *Am J Cardiol* 2012; 109(5):642-650.
13. Rosenmann D et al.: High-Frequency QRS Analysis Improves the Specificity of Exercise ECG Testing in Women Referred for Angiography, *J Electrocardiology* 2013; 46: 19-26.
14. Amit G et al.: Detection of Acute Myocardial Ischemia using High-Frequency QRS Analysis. *J Electrocardiol* 2008; 41(6) p. 636.
15. Amit G et al.: High-Frequency QRS Analysis in Patients with Acute Myocardial Infarction—A Preliminary Study, *Ann Noninv Electrocardiol* 2013; 18(2): 149-156.
16. Galante O et al.: Analysis of Depolarization Abnormalities in the Evaluation of Patients with Chest Pain, *Eur Heart J* 2011; 729, P4184.
17. Galante O et al.: Analysis of Depolarization Abnormalities in the Evaluation of Patients with Acute Chest Pain. *The 59th Annual Meeting of the Israel Heart Society*, Tel-Aviv, April 16-17 2012.
18. Amit G. et al.: Ischemia Monitoring by Analysis of Depolarization Changes. *Computers in Cardiology* 2008; 35:377-380.
19. Luria O. et al.: Ischemia Monitoring using High-Frequency QRS Analysis, The 12th International Dead Sea Symposium (IDSS), Tel-Aviv, March 3-5 2014.